

## Sleep Electroencephalograms and Sleep Stages in Hypoparathyroidism

Yukio Fukuyama and Masatsugu Hayashi

Department of Pediatrics, Tokyo Women's Medical College, Tokyo, and Department of Psychiatry and Behavioral Science, Tokai University School of Medicine, Kanagawa

**Key Words.** Sleep EEG · Sleep stages · Overnight polygraphy · Mitten pattern · Hypoparathyroidism · Hypocalcemia

**Abstract.** 2 patients with hypoparathyroidism, one idiopathic and the other pseudoform, were studied by overnight polygraphic recording of the sleep EEG and related activities before and after start of treatment to investigate their sleep EEG patterns and stages, with the results as follows.

(1) Conspicuous abnormalities were noted in the sleep record, namely, disappearance of humps, spindles and hill waves, emergence of the mitten pattern and rather monotonous delta rhythm bursts. The EEGs, both awake and asleep, showed findings suggestive of a possible disorder of the desynchronizing mechanism of the brain stem. Normal sleep EEG patterns were restored after the serum calcium level had returned to the normal range.

(2) In the course of overnight sleep, disturbance in the cyclic changes of sleep EEG pattern and absence of REM sleep were observed. Restoration to the normal course of sleep was achieved following the normalization of serum calcium level. Divalent calcium ion is considered to have intimate bearing upon the mechanism whereby synaptic chemical transmitters are activated. When viewed with reference to the monoamine hypothesis of Jouvet, the disturbance in the course of sleep observed in the present cases, especially the absence of or disturbed REM sleep, is inferred to be related to the hypocalcemia.

### Introduction

It is generally recognized that parathyroid glands play a principal role in maintaining the normal circulating level of ionized calcium and a variety of CNS manifestations result from their functional impairment. In hypoparathyroidism, either of true or pseudo type, tetany, epileptoid attacks and EEG abnormalities are

frequently observed with the underlying hypocalcemia. As for relations of these clinical manifestations and hypocalcemia, studies have been reviewed by *Gotta and Odoriz* (1948), *Alajouanine et al.* (1954), *Roth and Nevsimal* (1964), *Miura et al.* (1968), *Endo et al.* (1971), *Oguchi et al.* (1974) and *Hara et al.* (1974) and experimental studies in parathyroidectomized and thyroidectomized animals were reported by

*Corriol et al.* (1969). However, all these works primarily dealt with findings in the awake records and were neither concerned with sleep records nor investigations on the course of sleep. The purpose of the present paper is to describe the results of our recent investigation on the sleep EEG patterns and process of sleep recorded by overnight polygraphic tracings in each case of idiopathic and pseudo type of hypoparathyroidism.

**Subjects**

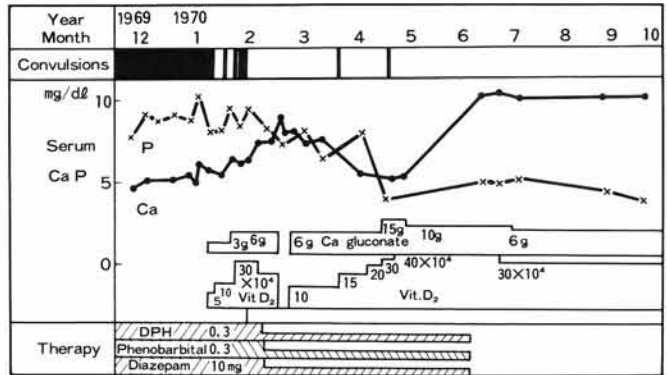
Subjects studied were a 12-year-old boy (case 1) and an 8-year-old girl (case 2) with symptoms of tetany and epileptoid attacks. From the clinical mani-

festations and by the criteria of *Albright et al.* (1942) and *Elrick et al.* (1950), case 1 was diagnosed as pseudohypoparathyroidism (PsH) and case 2 as idiopathic hypoparathyroidism (IdH), respectively. Both patients responded remarkably well to high-dose calcium and calciferol therapy. The pertinent clinical data from these cases are shown in figures 1 and 2.

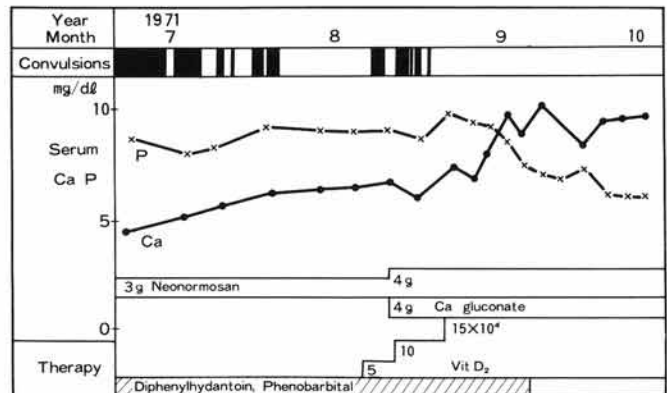
**Procedure**

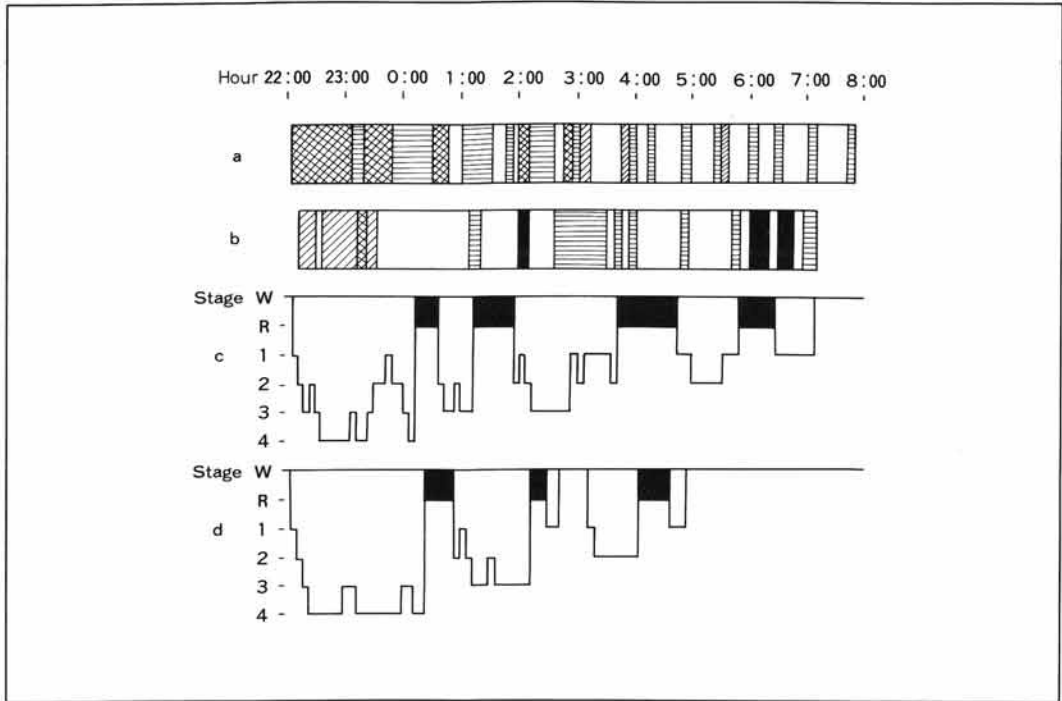
The sleep EEG patterns and course of sleep were studied in both cases through analysis of sleep diagrams prepared from overnight EEG records or from overnight polygraphic recordings in addition to the routine awake EEG records. The polygraphic records were made as follows: The EEG, ocular movements, electromyograms of the mentalis muscles and electrocardiograms (ECG) were recorded simultaneously by

**Fig. 1.** Case 1. Pseudohypoparathyroidism. Clinical course.



**Fig. 2.** Case 2. Idiopathic hypoparathyroidism. Clinical course.





**Fig. 3.** Case 1. Electroencephalographic sleep diagram. □ = A low-amplitude theta rhythm phase with intermixed slow alpha waves in all leads. ▨ = A moderate-amplitude theta rhythm phase with intermixed delta waves in all leads. ▩ = A moderate- to high-amplitude delta rhythm phase with intermixed theta waves in all leads. ▪ = A stage characterized by

diffuse, high amplitude delta rhythm bursts. ■ = REM sleep stage. **a** Before treatment. **b** 10 months after the start of treatment with calcium and vitamin D. **c** At 18 months of treatment, e.g., a year after the normalization of serum calcium level. **d** 5 years later.

means of a 13-channel, multi-purpose electroencephalograph with the patient placed in supine position in a shield-recording chamber used for routine EEG tracing. For EEG by unipolar lead, electrodes were placed on the head, at locations  $Fp_1$ ,  $Fp_2$ ,  $C_3$ ,  $C_4$ ,  $T_3$ ,  $T_4$ ,  $O_1$  and  $O_2$ , and one indifferent electrode on each earlobe ( $A_1$ ,  $A_2$ ), in accordance with the 10–20 system. Horizontal ocular movements were recorded by bipolar leads with a time constant of 1.5 with metal disc electrodes, 5 mm in diameter, placed 1 cm lateral to the outer canthus on each side. Electromyograms were recorded from the mentalis-mentalis inferioris muscles with a time constant of 0.05, and electrocardiograms by the standard limb leads. The depth of sleep as viewed from EEG patterns was rated on a six-point scale according to the Association for

the Psychophysiological Study of Sleep (APSS) criteria (*Rechtschaffen and Kales, 1968*), i.e. stages W, 1 through 4 and REM. In both cases, nevertheless, there occurred sleep stages at which the depth of sleep could hardly be rated due to abnormalities in the sleep records before and after therapy, which eventually made it impractical to make up the sleep diagrams. The EEG findings under such circumstance were shown simply as EEG patterns classified according to the provisional criteria as shown in figure 3. In the meantime, the overnight polygraphic tracings were not made for any consecutive night and, consequently, the data obtained fail to provide information as to the first night effect. Accordingly, no attempt was made in the present study to determine the incidence of individual stage of sleep.

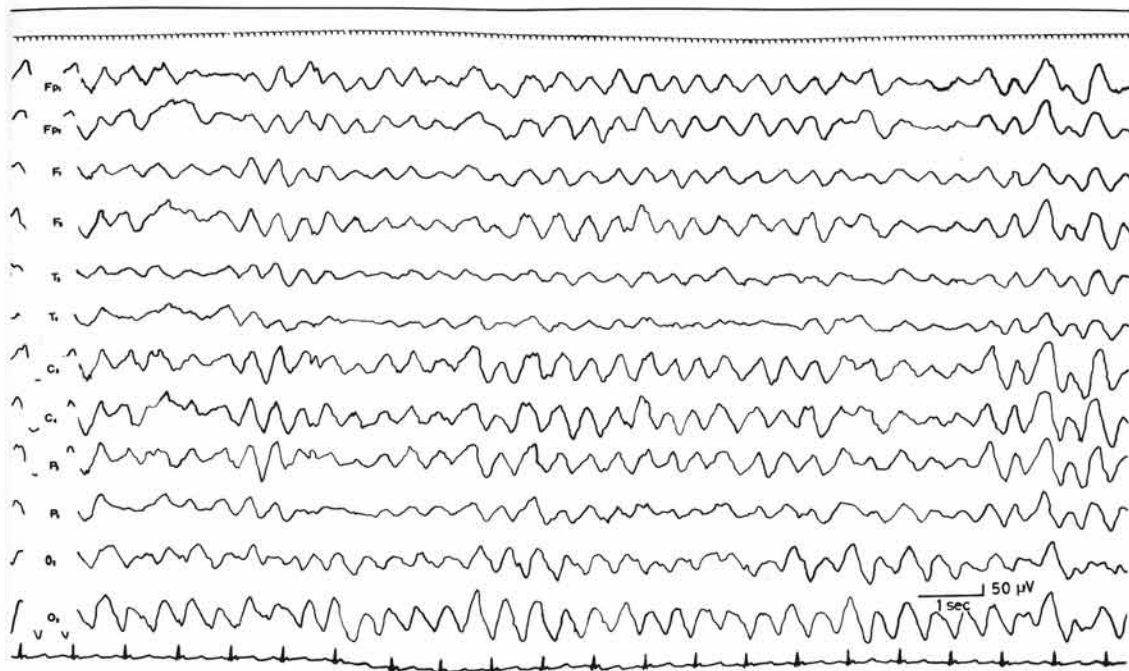


Fig. 4. Case 1. Awake electroencephalogram in pretreatment period.

## Results

### Case 1 (PsH)

The EEG tracings obtained before and 10 months after the start of treatment revealed abnormal sleep patterns which made the classification by the APSS criteria impractical and, therefore, the sleep EEG patterns were classified tentatively by the criteria shown in figure 3 and materialized to depict the patient's course of sleep records. Prior to treatment (the serum calcium level, 4.6–5.6 mg/100 ml), there was a marked slowing of background activity with diffuse delta rhythm bursts in the awake record (fig. 4), and the sleep record showed conspicuously inconsistent alterations with remarkable irregularities in the cyclic changes of sleep

patterns (fig. 3a). It was noteworthy that rather monotonous, diffuse high-amplitude delta waves, differing from a hill wave, appeared repeatedly over an extended duration (fig. 5) and that the so-called mitten pattern (type B) was noted on both frontal areas during the stage of moderate amplitude theta rhythm with intermixed delta waves (fig. 6). Throughout the course of sleep neither humps nor spindle waves appear; and, moreover, rapid ocular movements or lowering of amplitude of EMG activity never occurred; hence no evidence of REM sleep. The sleep records obtained 10 months after the initiation of treatment or about 4 months following normalization of the serum calcium level (fig. 3b) demonstrated a substantial diminution of the monotonous diffuse high-amplitude delta rhythm and the mitten pattern which had characterized the pretreatment sleep records, and showed small amounts of atypical spindle waves as well as rapid eye movements

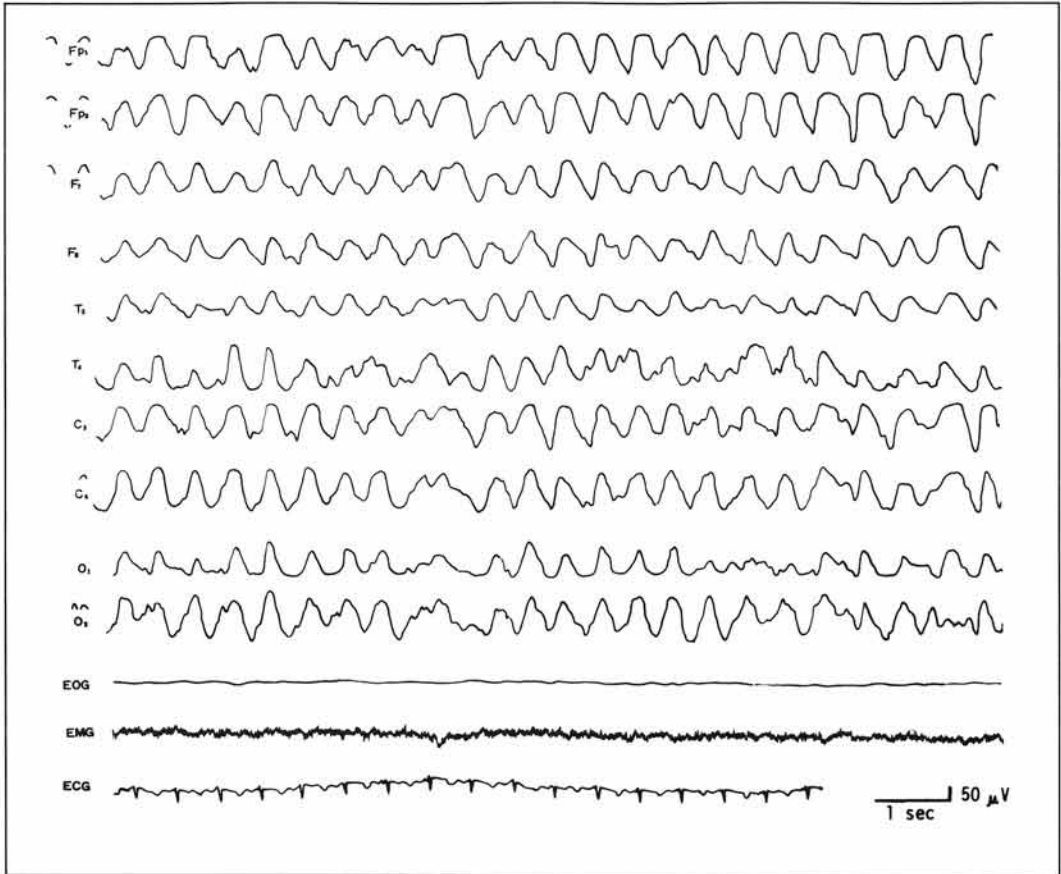


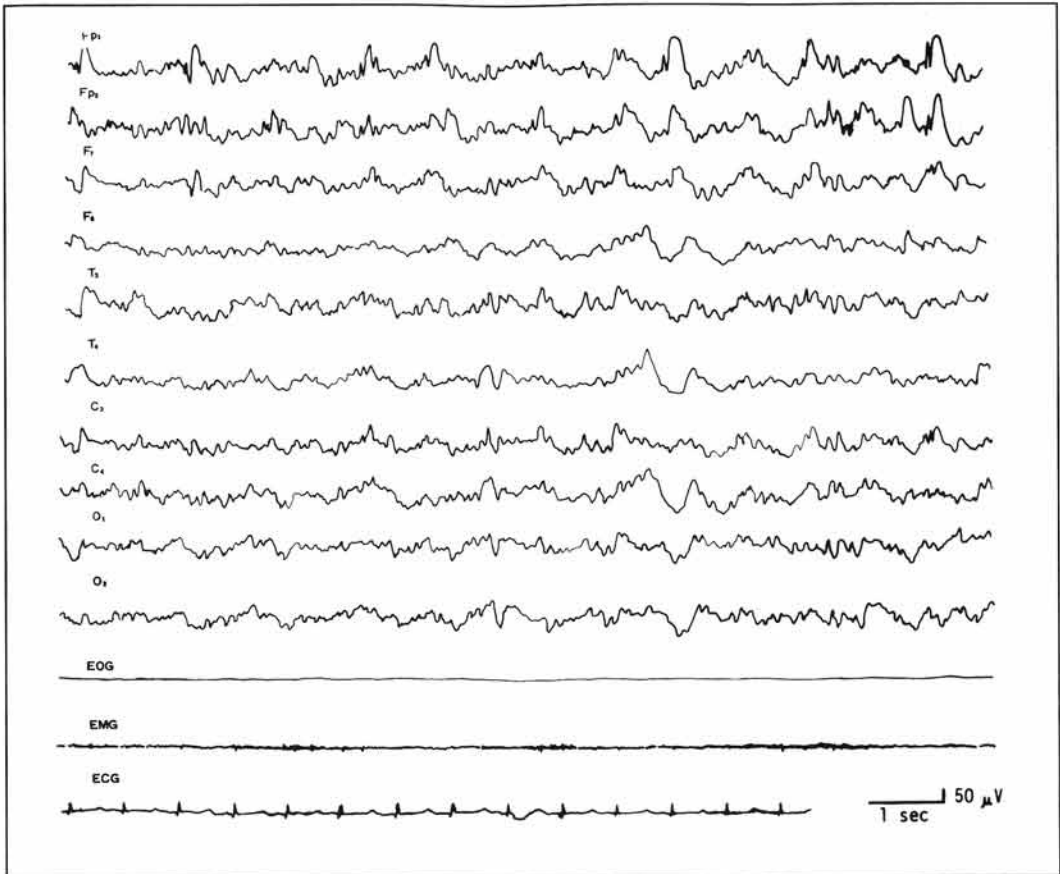
Fig. 5. Case 1. Diffuse monotonous high-amplitude delta waves in overnight polygraphic recording in pretreatment period.

and also a pattern characteristic of paradoxical sleep. At 18 months of treatment, that is, a year after the normalization of the serum calcium level (fig. 3c), the sleep record became to show a normal sleep EEG pattern consisting of typical hill waves and spindle waves with regularly cyclic NREM-REM sleep alternations and there no longer existed monotonous diffuse high-amplitude delta waves or mitten patterns. The tracings obtained 5 years after the initiation of treatment (fig. 3d) demonstrated nor-

mal sleep patterns with regular cyclic changes but at the same time they revealed 6 Hz positive spikes on temporal and occipital areas bilaterally during stage 2 and stage REM sleeps. The latter finding had been demonstrable even by the routine EEG (sleep activation records) since 2 years before.

#### Case 2 (*IdH*)

Slowed background rhythm with spike and wave complexes was noted in the awake record obtained before treatment (serum calcium level, 5.0 mg/100 ml) (fig. 7). The pretreatment sleep EEG record consisted over 60% of low-amplitude slow waves with occasional traces of humps but there were virtually no sleep spin-



**Fig. 6.** Case 1. Bifrontal dominant mitten pattern (type B) in overnight polygraphic recording in pre-treatment period.

dles or hill waves nor was there any regular cyclic change of sleep pattern (fig. 8a). 1 month after the start of treatment or 3 weeks after the serum calcium concentration had returned to the normal range, normal sleep EEG records with typical humps, spindles and hill waves and with recovery of the cyclic changes of sleep pattern were observed (fig. 8b). The records made on these two occasions did not provide data to confirm whether there might be any paradoxical sleep pattern or not, since poly-

graphic tracings were not done. 4 years after the initiation of treatment, the overnight tracings revealed normal sleep EEG with cyclic NREM-REM alternations, although the record was interrupted in the midst of tracing because of awaking for urination (fig. 8c).

### Discussion

There have been many reports on awake electroencephalography of hypoparathyroidism, as mentioned before. The findings noted in the present cases included slowed background rhythms, a marked build-up evoked by hyperventilation, spike and wave complexes

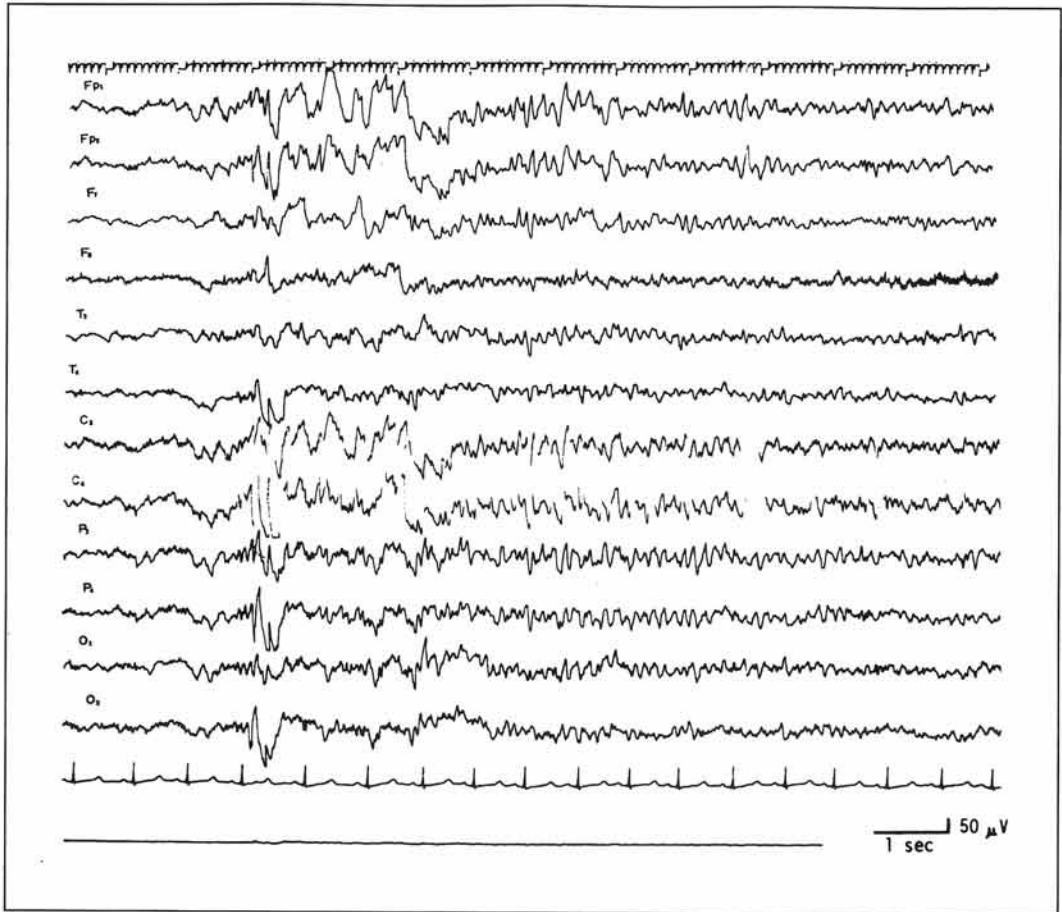


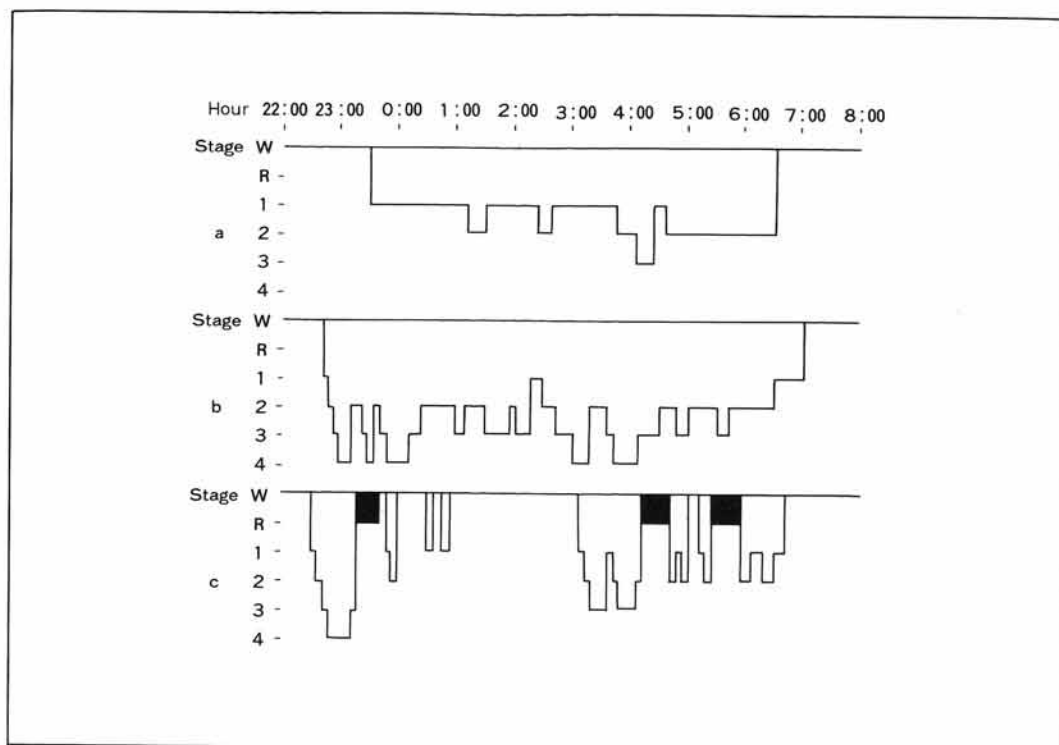
Fig. 7. Case 2. Awake electroencephalogram in pre-treatment period.

and slow wave bursts. It was also observed that normalization of EEG did not necessarily parallel with that of serum calcium level and that changes in serum calcium concentration were closely related to development and remission of tetany or epileptiform attacks in these cases. Inasmuch, however, as evaluation of these findings is not the purpose of this paper, we would like to proceed now to analysis of sleep EEG tracings and the course of sleep.

#### *Sleep EEG Patterns*

Several findings of considerable interest were noted in the present study as to sleep EEG tracings obtained by overnight polygraphic recording. Namely, (1) sleep spindles did not appear (in both cases) while the so-called mitten pattern (case 1) and rather monotonous delta rhythm bursts with lack of hill waves (case 1) were observed during the stage where the circulating level of calcium was lowered; (2) atypical spindle waves appeared (in both cases) with concomitant remarkable decrease of the mitten pattern and monotonous delta bursts and emergence of typical hill waves (case 1) after lapse of a considerable length of time





**Fig. 8.** Case 2. Electroencephalographic sleep diagram. **a** Before treatment. **b** 1 month after the start of treatment. **c** 4 years later.

following normalization of the serum calcium level; (3) the sleep EEG pattern returned to normal a little more than a year after initiation of treatment but, at the same time, the sleep record became to show 6 Hz positive spikes (case 1).

In a case of PsH, *Nakamura et al.* (1975) observed synchronous spindles evoked by single, sudden stimulation in the frontal area and they have inferred disorder of the desynchronizing mechanism therefrom as well as from other clinical findings. Whilst disappearance of sleep spindles may not occur in all cases of hypoparathyroidism, the frequent emergence of mitten pattern (type B) in both

frontal areas concomitant with the disappearance of sleep spindles, and the subsequent emergence of sleep spindles in the same areas with disappearance of the mitten pattern after normalization of the serum calcium level, which were observed in case 1, are of profound interest when viewed with respect to relations of both wave patterns and to the mechanism of their formation. The mitten pattern was defined by *Gibbs and Gibbs* (1963) as follows: it is a pattern which contains fast and slow components, appears synchronously, primarily in both frontal areas during a moderately deep sleep stage (corresponding to stage 2 by the APSS criteria), and of which the thumb component is composed of the final wave of 6–12 Hz slow frontal spindles and is followed by a mitten-shaped hand portion slow component. They also described that the mitten pattern might be classifiable into three types according



to frequency of the thumb component, i.e. types A-1 (6–7 Hz), A (8–9 Hz) and B (10–12 Hz). Differentiation of type B mitten pattern from frontal spike-wave complexes was discussed and this particular type of mitten pattern was described to appear often in epilepsy (especially in that associated with psychic symptoms). Concerning the mechanism of appearance of this pattern, possible involvement of the base of the frontal lobe, thalamus and temporal lobe has been postulated by *Gibbs and Gibbs* (1963), that of the limbic system (frontal and anterior temporal regions) and diencephalic reticular formation by *Halász et al.* (1963), that of the specific and non-specific thalamic nuclei by *Kuramitsu et al.* (1968) and, from the correlation of the pattern with autonomic nervous symptoms, that of the brain stem reticular formation system and diencephalon by *Aono et al.* (1972). On the grounds that the mitten pattern was observed in the present study to emerge synchronously in both frontal areas during stage 2 as did sleep spindles, that the thumb component of this pattern is essentially comprised of the final wave of sleep spindles, and that the appearance of spindles occurred in parallel with the disappearance of the mitten pattern following normalization of serum calcium level, we are inclined to interpret the findings as indicating the mitten pattern being related to spindles and that the above-described mechanisms of development of thalamic spindles and synchronization may be involved in the emergence of this pattern. Furthermore, the fact that rather monotonous, bilateral synchronous delta rhythm bursts were observed in the awake records seems to suggest functional disorder of the brain stem, or the mesencephalic reticular formation in particular, as the desynchronizing mechanism. It would also follow that the above-described mitten pattern emerged as a

result of disturbance in typical sleep spindle formation due to interaction between mesencephalic reticular formation-thalamic specific nuclei and the thalamic nonspecific nuclei. Accordingly, it would be reasonable to assume that what is intensely affected by hypocalcemia in hypoparathyroidism might be the desynchronizing mechanism rather than the synchronizing mechanism.

#### *Course of Sleep*

There has as yet been no report of overnight polygraphic study of the course of sleep in cases of hypoparathyroidism or hypocalcemia. Clinically, there was no evidence of tendency to insomnia, somnolence or interruption of sleep in either case and the awake–sleep cycle was maintained in both cases while abnormalities in the sleep records were evident. Overnight polygraphic recording was made, therefore, and the results disclosed disturbance in the cyclic changes of sleep pattern both in cases 1 and 2 and absence of stage REM in case 1. Both the orderly cyclic changes of sleep pattern and REM sleep became restored following normalization of the serum calcium level, suggesting that the calcium regulating mechanism including parathyroid glands might be playing some role in the sleep mechanism, especially the mechanism of development of REM sleep. Relationship of divalent calcium ion to sleep was advocated by *Demole* (1927), *Cloetta et al.* (1934) and other investigators but later studies ruled out its possibility (*Asahina*, 1965). Since the discovery of REM sleep by *Aserinsky and Kleitman* (1953), and the advent of the monoamine hypothesis of *Jouvet* (1969), numerous neuropharmacological studies of the mechanisms of the NREM and REM sleeps have been published. However, to effect the function of such cerebral tissue amines and acetylcholine as

the chemical transmitters it is essential that these substances are synthesized, stored and liberated all in normal fashions without disturbance. There have been several experimental studies particularly pertaining to activation of the mechanism of liberation of these chemical transmitters of the nerve impulse, and the studies of *Miledi and Slater* (1966), *Yamamoto* (1970) and *Krnjević* (1974) demonstrated that  $Ca^{++}$  in the extracellular fluid is essential for the liberation of the chemical transmitters, and that removal of this divalent ion from the extracellular fluid results in a complete and reversible disappearance of the synaptic potential, the effect of  $Ca^{++}$  being antagonized by the action of  $Mg^{++}$ .

The monoamine hypothesis should be based on the premise that the mechanism of calcium maintenance is properly operating. It would be inferable as a possibility that, in hypoparathyroidism where the calcium maintenance mechanism is impaired, disorder of the mechanism of chemical transmitter release at the synapse might possibly occur, perhaps with consequent impairment of the mechanism by which REM sleep is produced. Nevertheless, whether a lowered circulating level of calcium may be directly reflected in changes of the synaptic calcium ion concentration and whether such disturbance of the course of sleep will be observed or not consistently in hypoparathyroidism or in hypocalcemia are the problems that are yet to be investigated. In addition, similar electroencephalographic changes such as the absence of sleep spindles may occur in different metabolic disorders such as hypoglycemia, hypothyroidism or inborn errors of amino acid metabolism, so one must be cautious about the interpretation of the finding, and further study on many cases of both genuine and pseudohypoparathyroidism will be mandatory.

## References

- Alajouanine, T.; Contamin, F.; Cathala, H.P. et Scherrer, J.: Etude critique de la délimitation clinique, humorale et électrophysiologique de la tétanie de l'adulte. *Presse méd.* 62: 137–138 (1954).
- Albright, F.B.; Smith, P.H., and Parson, W.: Pseudohypoparathyroidism, an example of 'Seabright-Bantam syndrome'. Report of three cases. *Endocrinology* 30: 922–923 (1942).
- Aono, T.; Ishige, Y., and Yashima, Y.: Mitten pattern and background EEG. *Psychiatry, Tokyo* 14: 33–39 (1972).
- Asahina, K.: Physiology of sleep (Chugai, Tokyo 1965).
- Aserinsky, E. and Kleitman, N.: Regularly occurring periods of eye motility and concomitant phenomena during sleep. *Science* 118: 273–274 (1953).
- Cloetta, M.; Fischer, H. und van der Loeff, M.R.: Die Biochemie von Schlaf und Erregung mit besonderer Berücksichtigung der Bedeutung der Kationen. *Naunyn-Schmiedebergs Arch. exp. Path. Pharmacol.* 174: 589–675 (1934).
- Corriol, J.; Papy, J.J.; Rohner, J.J., and Joanny, P.: Electroclinical correlations established during tetanic manifestations induced by parathyroid removal in dog; in Gastaut, Jasper, Bancaud and Waltregny, The physiopathogenesis of the epilepsies, pp. 128–140 (Thomas, Springfield 1969).
- Demole, V.: Pharmakologisch-anatomische Untersuchungen zum Problem des Schlafes. *Naunyn-Schmiedebergs Arch. exp. Path. Pharmacol.* 120: 229–258 (1927).
- Elrick, H.; Albright, F.B.; Bartter, F.C.; Forbes, A.P., and Reeves, J.D.: Further studies on pseudohypoparathyroidism: report of four new cases. *Acta endocr., Copenh.* 5: 199–225 (1950).
- Endo, M.; Takahashi, S., and Okada, F.: Idiopathic hypoparathyroidism. With special reference to EEG findings and epileptic seizures. *Clin. EEG, Kyoto* 13: 830–837 (1971).
- Gibbs, F.A. and Gibbs, E.L.: The mitten pattern. An electroencephalographic abnormality correlating with psychosis. *J. Neuropsychiat.* 5: 6 (1963).
- Gotta, H. and Odoriz, T.B.: The electroencephalogram in hypoparathyroidism with tetany and epilepsy. *J. clin. Endocr. Metab.* 8: 674–686 (1948).
- Halász, P.; Kajtor, F.; Pertrini, R.; Nagy, T.A., and Zásdányi, O.: Data on the diagnostic interpretation

- of 'mitten' potentials. *Electroenceph. clin. Neurophysiol.* 15: 340 (1963).
- Hara, T.; Miura, S.; Oguchi, T., and Mochizuki, Y.: EEG findings of hypoparathyroidism. *Clin. EEG, Kyoto* 16: 664-673 (1974).
- Jouvet, M.: Biogenic amines and the states of sleep. *Science* 163: 32-41 (1969).
- Krnjević, K.: Synaptic transmission in the brain; in Stevens, *Handbook of electroencephalography and clinical neurophysiology*, vol. 2/B, pp. 19-42 (1974).
- Kuramitsu, M.; Yanai, J., and Otsuka, T.: On mitten pattern. *Psychiatry, Tokyo* 10: 719 (1968).
- Miledi, R. and Slater, C.R.: The action of calcium on neural synapse in the squid. *J. Physiol., Lond.* 184: 473-498 (1966).
- Miura, S.; Mochizuki, N.; Komine, K., and Hara, T.: Idiopathic hypoparathyroidism presented with epileptic seizures - especially in relation to EEG findings. *Shindan Chiryō, Tokyo* 56: 2015-2027 (1968).
- Nakamura, M.; Fukui, Y.; Iwase, N.; Kadobayashi, I., and Kato, N.: A case of idiopathic hypoparathyroidism with astatic seizure-like response on startling. *Clin. EEG, Kyoto* 17: 690-604 (1975).
- Oguchi, T.; Mochizuki, Y.; Otani, Y.; Miura, S., and Hara, T.: Pseudohypoparathyroidism. Review of EEG findings in all reported Japanese cases including our case. *Clin. Psychiat., Tokyo* 3: 1205-1912 (1974).
- Rechtschaffen, A. and Kales, A.: A manual of standardized terminology, techniques and scoring system for sleep stage of human subjects (Public Health Service, US Government Printing Office, Washington 1968).
- Roth, B. and Nevsimal, O.: EEG study of tetany and spasmophilia. *Electroenceph. clin. Neurophysiol.* 17: 36-45 (1964).
- Yamamoto, C.: Separation of brain neurotransmitters. *Adv. neurol. Sci., Tokyo* 13: 878-884 (1970).

Received: August 9, 1977

Accepted: October 14, 1977

Prof. Yukio Fukuyama, Department of Pediatrics,  
Tokyo Women's Medical College, 10 Kawadacho,  
Tokyo 162 (Japan)